

# Advances In Prosthodontics™

New Findings & Best Practices for Cosmetic & Restorative Dentistry

## INSIDE THIS ISSUE

### CASE SUMMARY:

Restoration Redo on an Angled Implant

Background  
pages 1-2

Findings and  
Treatment Options  
page 2

Treatment Steps,  
Primary Challenge,  
and Clinical Note  
page 3

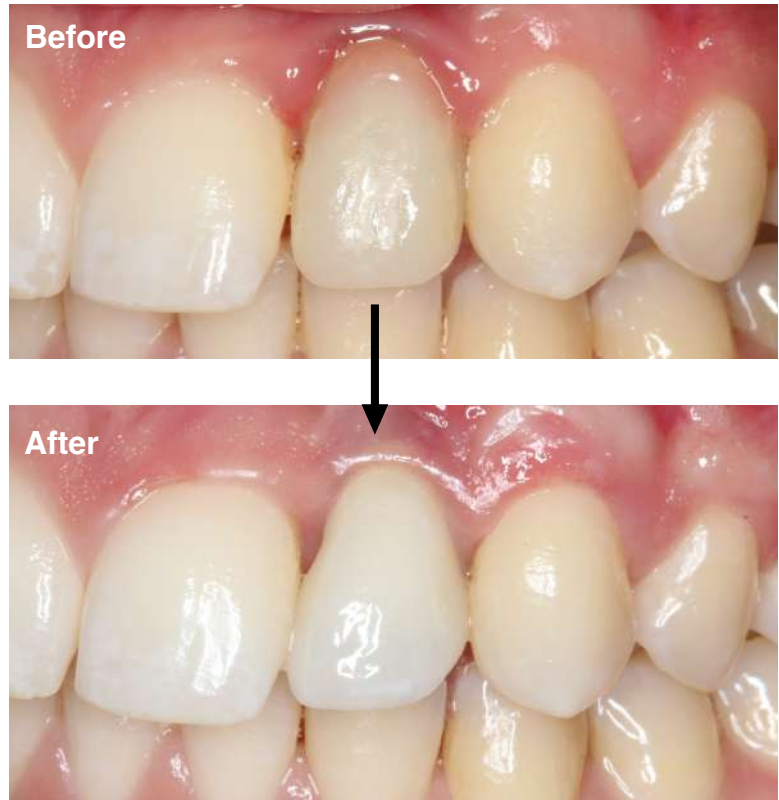
Final Result  
page 3

### COMPLEX CASES:

Dr. Jacobs' Specialized  
Training & Skill Help with  
Patients in These  
Situations...  
page 4

© Sams Media Group, LLC

## Do You Have a Patient with a Failing Restoration?



Here's the story of a patient who was referred from another dental professional...

If you have a patient with several missing, broken or severely worn teeth — or failing restorations — they may be a candidate for an oral rehabilitation with the assistance of an advanced Prosthodontist.

Read more on the next page...

## ◆ Do you want another opinion on a complex case? Or to talk and share ideas?

There are many ways we can help each other by working together on complex cases and by sharing knowledge and experience. With your reputation for quality dental care, and my experience with restorative treatments, we can work together on advanced cases and both benefit! If you'd like to discuss a treatment, or talk on the phone about how we can help each other, please call or email my office with specific days and times when you're available.

### Prosthodontic Publication

#### Want to see recent issues?

Stay informed on new findings and best practices for cosmetic and restorative dentistry. See more examples of complex cases online at:

**AdvancedProsthodontist.com**  
/ Jacobs



## CASE SUMMARY: Restoration Redo on an Angled Implant

by Bryan Jacobs, DMD, MS, *Board Certified Prosthodontist*

Patient “Brittney” was 23 years old when she presented to my office for prosthetic management of a poorly positioned implant. Brittney had a congenitally missing left lateral incisor (#10). When she was younger, this incisor required various temporary measures. Eventually, a specialist near her out-of-state home grafted the site and in a second surgery placed an implant. Her general dentist told her a “mistake” was made when the implant was placed and provisionalized the implant with a cement-retained crown.

**Exam Findings:** Relative to an ideal prosthetically-driven implant position, the implant at site #10 was placed shallow and with a severe facial/buccal angulation. It was fully housed in bone. The peri-implant soft tissues were erythematous and an open mesial contact was trapping plaque.

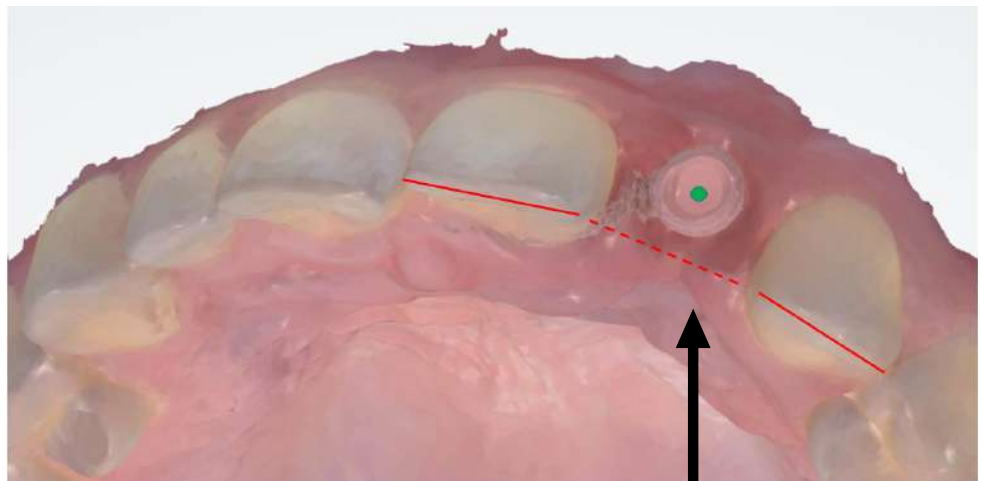
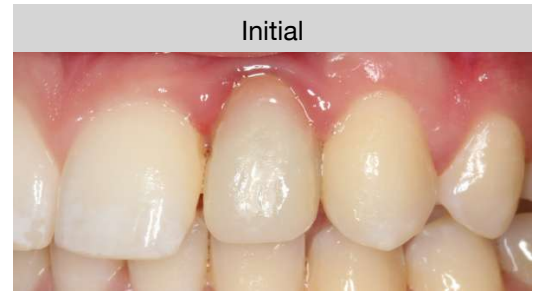**As a prosthodontist,** I have experience repairing or replacing dental restorations whether they are complete or partial dentures, dental implants, crowns, or bridges.

**Treatment Options:** The clinical and radiographic findings were discussed with Brittney. A number of options were given:

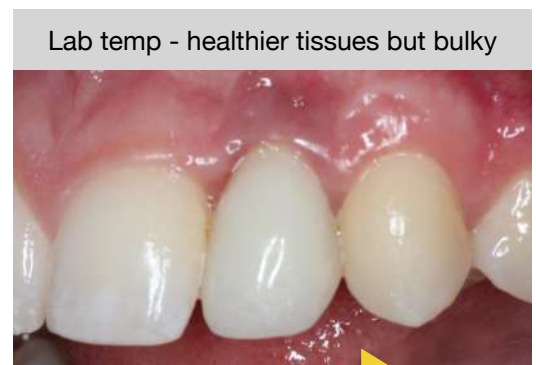- (1) Take out the temporary, undergo soft tissue grafting with a periodontist, then fabricate a new temporary and a final restoration.
- (2) Place a screw-retained provisional, assess esthetics and referral for grafting as necessary before a final restoration.
- (3) Remove the implant and start over.

**After removing the existing temporary to evaluate,** it was advised that the best esthetic result would require implant removal, as well as possible esthetic restoration of other anterior teeth. Brittney discussed the options with her family and ultimately decided to pursue option #2 (from above), understanding that there may be an esthetic compromise. She did not want to restore any adjacent teeth.

Continued on next page...



A view down the long axis of the implant scan body (green circle) shows the straight-line screw access relative to the approximate incisal edge



Final photos on next page...

### ◆ Do you have a patient in Brittney’s situation? Or another complex case?

If you have a question about a case and want another opinion, give my office a call. Or, if there’s a case that you want to work together on, please fill out and send in the enclosed referral form.

My office and I will take great care of your patient and keep you informed. Dental professionals refer to me as **The Complex Case Specialist™** because I perform complex cases every day.

### Treatment Steps:

- A screw-retained provisional with angled screw-access channel was fabricated, placed, and allowed to sit for 10 weeks. This allowed more ideal tissue contouring and the ability to ensure resolution of the gingival inflammation.
- Once this was achieved, a final screw-retained restoration was fabricated and seated. The final restoration was a custom shaded all-ceramic crown on a gold-shaded custom abutment, with an angled screw-access channel. Brittney was very pleased with the result.

### Primary Challenge:

For this case, expectation management was the primary challenge. Using the implant “as-is” would not allow ideal esthetics. The mesial-distal width of the space, the shape of the centrals, and especially the implant angulation are working against the esthetic goals.

However, it is not unreasonable (or unusual) for a patient who has been through years of treatment to just want to be done in a way that maintains their health and meets their own expectations. This is where Brittney was at, and I was happy to meet her there and help her move forward.

### Clinical Note:

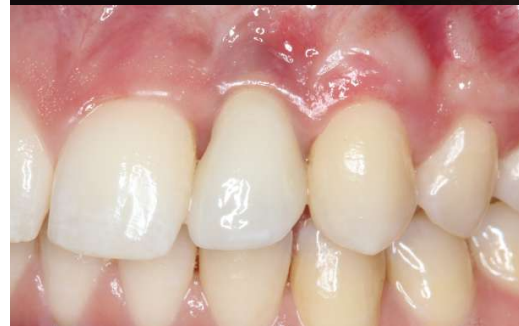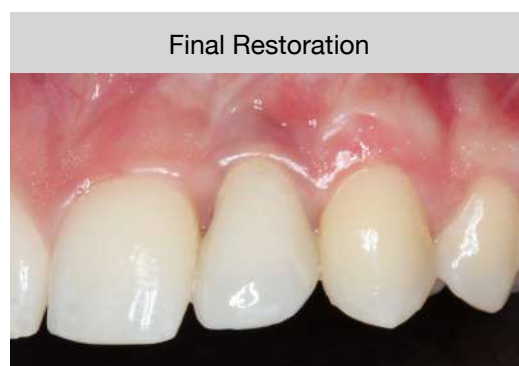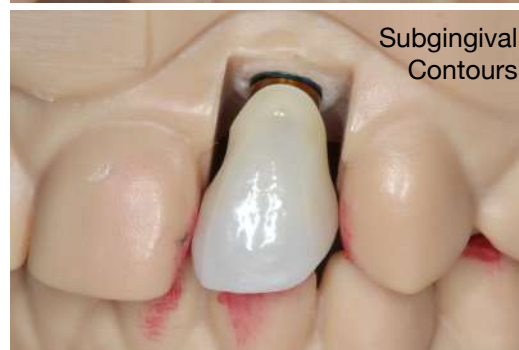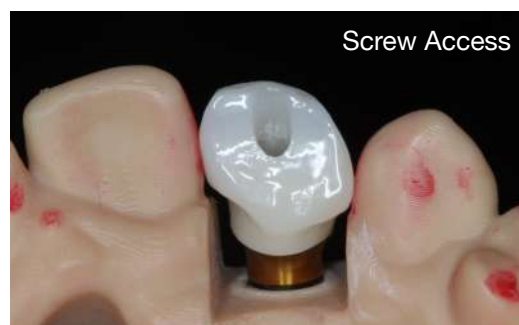Notice the customized concave shape of the sub-gingival contour of the restoration — this allowed for tissue health and a more realistic result!

**If you have a patient with a complicated dental problem** and you would like assistance in helping them, please contact me. It will be my pleasure to help with diagnosing, planning, or treatment execution for complex cases.

**When patients are referred,** I refer them back to their general dentist for regular hygiene, unless advised otherwise by the referring office, depending on the patient and treatment. I will be in contact with your office every step of the way.

If you have comments / questions about this example, or my prosthodontic protocols, please email me at:

**[bryanjacobs@dentalprofessionals.com](mailto:bryanjacobs@dentalprofessionals.com)**



## ◆ How can a Board Certified Prosthodontist assist you and your dental team?

I specialize in the treatment of complex cases, usually involving several procedures over months of care.


The next time you see a challenging case, please feel free to call me and we can discuss treatment planning or I can help you with any part of the treatment.

My goal is to be a resource for your office by helping manage difficult and time-consuming procedures, restoring the function and esthetics that the patient desires, then referring them back to your office for their ongoing care.



# Dr. Bryan Jacobs

DMD, MS, Prosthodontist ♦ The Complex Case Specialist™



## About Dr. Jacobs' specialization:

As a Prosthodontist, Dr. Bryan Jacobs specializes in fixed and removable prostheses, dental implants, and all phases of esthetic dentistry. Dr. Jacobs is Board Certified by the American Board of Prosthodontics. His training and experience make treatments of complex cases more successful, including the following examples:

- Patients with ill-fitting dentures, severely worn or damaged teeth can receive a single dental implant or a full arch of natural-looking teeth.
- Patients who have suffered from traumatic injury, congenitally missing teeth, or a chronic condition can receive oral prostheses, which may be a combination of dental implants, crowns, bridges, or veneers.
- Patients with severe neglect of their oral health can receive a full reconstruction to restore function and esthetics.

*Dr. Bryan Jacobs practices prosthodontics at Dental Professionals in Chicago and Skokie, working with GP's and other dental specialists to restore the smiles and confidence of patients facing a difficult diagnosis.*

### Personal Message To Fellow Dental Practitioners:

"As the referring dentist, you know your patient's mouth and have key insight into your patient's needs. I want to work with you to provide your patients with the best possible treatment outcomes. I will treat your patient in a manner that will reflect well on you and strengthen your relationship with your patient. I am here to make you look good! When your patient's care is completed, they are referred back to your office for their ongoing dental care. I am grateful for your collegueship and trust with your patients!"

Dr. Jacobs' online referral form at: [DentalProfessionals.com/referring-doctors](http://DentalProfessionals.com/referring-doctors)

### Protho Pledge

When your patient is referred:

- ✓ I will only treat what your patient needs.
- ✓ I will send you updates.
- ✓ I will be part of your team, not take over your patients.

## ◆ Why other dental professionals work with a Board Certified Prosthodontist

Board Certified Prosthodontists are specialists in implant, esthetic, and reconstructive dentistry.

- 1. You have a patient requiring treatment outside your typical scope of practice.**  
Examples include patients with vertical dimension discrepancies, severely resorbed ridges, inadequate interarch space, severe bruxism, traumatic tooth loss, or congenital abnormalities.
- 2. You have a patient with complex needs that may drain your time.**  
If your patient may require treatment from several specialists, Board Certified Prosthodontists can help because they are trained to appropriately stage and manage complex treatment plans.
- 3. You have a demanding patient who wants perfect esthetics.**  
Examples include patients with a high smile line or needing a single tooth replacement in the esthetic zone. Board Certified Prosthodontists are trained in selecting the best solutions for high-demand patients.
- 4. You have a question and want to discuss a case with a colleague to ease your mind.**  
Board Certified Prosthodontists can be an excellent resource for you to ask questions because they are trained in many types of complicated treatments. For example, you may want to consult a Board Certified Prosthodontist for complex implant-supported restorations. They can work with you or complete the treatment for you to achieve the best in both function and esthetics.