

# Advances In Prosthodontics™

New Findings & Best Practices for Cosmetic & Restorative Dentistry

## INSIDE THIS ISSUE

### CASE SUMMARY:

Do You Have a Patient With This Situation? (see photos on right)... pages 1-2

### DENTAL JOURNAL BRIEF:

Quickly Get the Latest Research on Procedures & Materials For Better Outcomes... page 3

### HAVE A LAUGH:

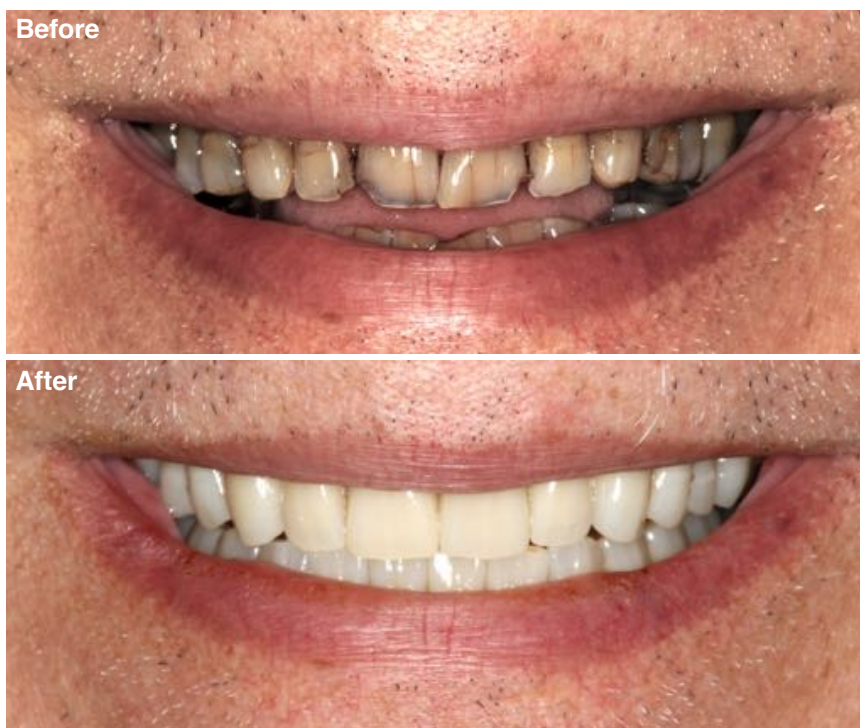Dental Potty Humor... page 3

### COMPLEX CASES:

Dr. Jacobs' Specialized Training & Skill Make These Treatments More Successful... page 4

© Sams Media Group, LLC

## Do You Have a Patient with High Esthetic Demands?



**Here's the story of a patient who was referred from another dental professional...**

If you have a patient with several missing, broken or severely worn teeth—or potentially high esthetic demands—they may be a candidate for oral rehabilitation with the assistance of an advanced Prosthodontist.

**Read more on the next page...**

### ◆ Do you want another opinion on a complex case? Or to meet and share ideas?

There are many ways we can help each other by working together on complex cases and by sharing knowledge and experience.

With your reputation for quality dental care, and my experience with restorative treatments, we can work together on advanced cases and both benefit!

If you'd like to meet to discuss a treatment, or talk on the phone about how we can help each other, please call or email me with specific days and times when you're available to talk or meet.

## CASE SUMMARY: Full Mouth Rehabilitation

Dr. Bryan Jacobs, Prosthodontist

Patient “Roberto” came via referral from a general dentist to discuss prosthetic rehabilitation. He had a significant anterior open bite—unchanging—but affecting his ability to eat comfortably. Also, Roberto’s spouse wanted him to improve his smile. He made it clear that he did not want bright white teeth, but rather very natural appearing features and anatomy, befitting a “European gentleman.”

Complicating factors for his treatment included only two one-month intervals in the US over a six month period, with all other time spent in Europe. Additionally, he had a prior diagnosis of obstructive sleep apnea (OSA), which was being treated with oral appliance therapy. He requested during treatment with me that he not go a single night without the ability to wear an OSA appliance.

**As a prosthodontist**, I have experience with complex cases and coordinating with a patient’s general dentist and other specialists to achieve the best function and esthetics.

**In month 1**, prosthetic records were made and a series of plans were developed. Roberto opted for full mouth rehabilitation. A fairly old existing single implant was identified and appropriate impressions parts ordered. A single third molar was extracted due to a localized periodontal defect, and a digital diagnostic wax-up was completed.

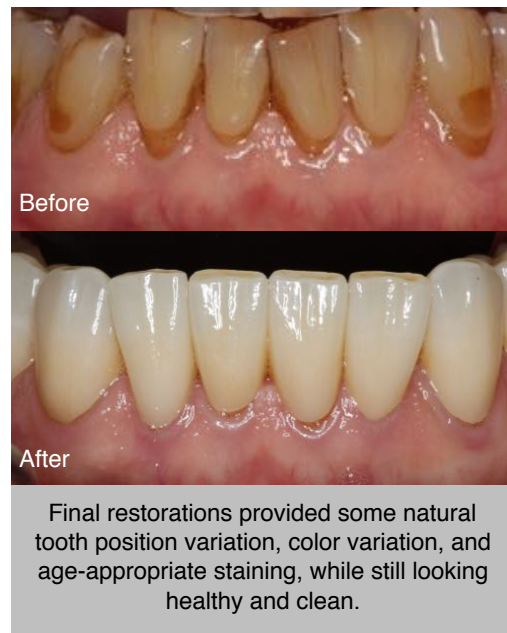**Upon returning for his second month in Chicago**, all of Roberto’s teeth were prepared (with the exception of the three remaining third molars) over the course of two visits, with provisionalization based on the digital design. With extensive pre-planning, the final case (full zirconia crowns) was seated and a new OSA appliance fabricated with his dental sleep specialist prior to Roberto again departing the country.

**An interesting challenge was** ensuring Roberto had an OSA appliance every night throughout the course of his treatment. After considering different approaches, the chosen approach worked well:

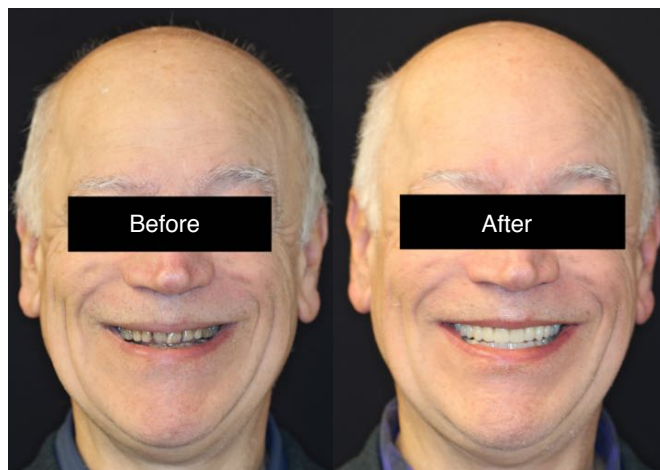- After seating an arch of provisional restorations, a fast-set stone cast was produced from an alginate impression.
- The corresponding segment of the sleep appliance was then tried on this cast with a fit-checking medium. It was relieved as needed until a passive fit could be achieved.
- Then, the appliance was relined on the cast with a light body PVS material and trimmed accordingly. Intraoral fit and comfort was confirmed.
- This was repeated after seating the final restorations as well—yielding a temporary solution until the new appliance was ready.

I gave Roberto my full warranty and sent him back to the referring office for long-term care. I give all referred patients a warranty and refer them back to the general dentist for regular hygiene unless advised otherwise by the referring office, depending on the patient and treatment. If you have comments or questions about this example, please email me at:

[bryanjacobs@dentalprofessionals.com](mailto:bryanjacobs@dentalprofessionals.com)



Final restorations provided some natural tooth position variation, color variation, and age-appropriate staining, while still looking healthy and clean.



### ◆ Do you have a patient in Roberto’s situation? Or another complex case?

If you have a question about a case and want another opinion, give my office a call. Or, if there’s a case that you want to work together on, please fill out and send in the enclosed referral form.

My office and I will take great care of your patient and keep you informed. Dental professionals refer to me as **The Complex Case Specialist™** because I perform complex cases every day.

Quickly Get the Latest Research On Procedures & Materials For Better Outcomes...

## Long-term evaluation of cantilevered versus fixed-fixed resin-bonded fixed partial dentures for missing maxillary incisors

Botelho MG, Chan AW, Leung NC, Lam WY. J Dent. 2016 Feb;45:59-66.  
doi: 10.1016/j.jdent.2015.12.006. Epub 2016 Jan 3.

### OBJECTIVES:

To evaluate the long-term longevity and patient-reported outcomes of two-unit cantilevered (CL2) and three-unit fixed-fixed (FF3) resin-bonded fixed partial dentures (RBFDPs) for the replacement of a maxillary permanent incisor.

### MATERIALS AND METHODS:

Twenty-eight subjects were randomly assigned to receive either a CL2 or FF3 RBFDP placed by one operator. Prosthesis longevity was determined by clinical examination and history. Success was defined as absence of complications requiring intervention and survival as retention of the original prosthesis in mouth. Subjects' satisfaction was assessed using visual analogue scale (VAS) and oral health-related quality of life (OHRQoL) using Oral Health Impact Profile (OHIP-49). Outcomes were analysed with t-test/Mann-Whitney U test, chi-square and log-rank test at significance level  $\alpha=0.05$ .

### RESULTS:

Twenty-two subjects were reviewed. Thirteen of fifteen CL2 and ten of fourteen FF3 RBFDPs were examined (79.3 percent response rate) with a mean service life of  $216.5 \pm 20.8$  months. All CL2 RBFDPs survived with no complications while only 10 percent of FF3 experienced no complications and only 50 percent of them survived (both  $P=0.000$ ). CL2 had a significantly better success and survival rate than FF3 ( $P=0.000$  and  $P=0.009$ , respectively). There was no significant difference in subjects' satisfaction and OHRQoL apart from CL2 group subjects had a higher satisfaction in cleaning of the prosthesis ( $84.1 \pm 13.6$ ) than FF3 group ( $72.6 \pm 11.7$ ) ( $P=0.05$ ).

### CONCLUSIONS:

Two-unit cantilevered RBFDPs were observed to have a significantly better success and survival than the FF3 design for the replacement of a maxillary incisor. Good patient-reported outcomes have been found for RBFDPs in single-tooth replacement in aesthetic zone.

### ◆ Have A Laugh: Dental Potty Humor


I hope I made you smile during your busy day! I take the care of patients referred to me very seriously, including knowing how to educate them so they feel comfortable. I specialize in the treatment of complex cases, usually involving several procedures over months of care.

The next time you see a challenging case, please feel free to call me and we can discuss treatment planning or I can help you with any part of the treatment. My goal is to be a resource for your office by helping manage difficult and time-consuming procedures, restoring the function and esthetics that the patient desires, then referring them back to your office for their ongoing care.



# Dr. Bryan Jacobs

DMD, MS, Prosthodontist ♦ The Complex Case Specialist™



## About Dr. Jacobs' specialization:

As a Prosthodontist, Dr. Bryan Jacobs specializes in fixed and removable prostheses, dental implants, and all phases of esthetic dentistry.

Dr. Jacobs' prosthodontic training and experience make treatments of complex cases more successful, including the following examples:

- Patients with ill-fitting dentures, severely worn or damaged teeth can receive a single dental implant or a full arch of natural-looking teeth.
- Patients who have suffered from traumatic injury, congenitally missing teeth, or a chronic condition can receive oral prostheses, which may be a combination of dental implants, crowns, bridges, or veneers.
- Patients with severe neglect of their oral health can receive a full reconstruction to restore function and esthetics.

*Dr. Bryan Jacobs practices prosthodontics at Dental Professionals in Chicago and Skokie, working with GP's and other dental specialists to restore the smiles and confidence of patients facing a difficult diagnosis.*

## Personal Message To Fellow Dental Practitioners:

"As the referring dentist, you know your patient's mouth and have key insight into your patient's needs. I want to work with you to provide your patients with the best possible treatment outcomes. I will treat your patient in a manner that will reflect well on you and strengthen your relationship with your patient. I am here to make you look good! When your patient's care is completed, they are referred back to your office for their ongoing dental care. I am grateful for your collegueship and trust with your patients!"

Dr. Jacobs' has an easy online referral form at:  
[DentalProfessionals.com/referring-doctors](http://DentalProfessionals.com/referring-doctors)

### Protho Pledge

When your patient is referred:

- ✓ I will only treat what's been referred.
- ✓ I will send you updates.
- ✓ I will be part of your team, not take over your patients.

## ◆ Why other dental professionals work with a Certified Prosthodontist

Certified Prosthodontists are specialists in implant, esthetic, and reconstructive dentistry.

### 1. You have a patient requiring treatment outside your typical scope of practice.

Examples include patients with vertical dimension discrepancies, severely resorbed ridges, inadequate interarch space, severe bruxism, traumatic tooth loss, or congenital abnormalities.

### 2. You have a patient with complex needs that may drain your time.

If your patient may require treatment from several specialists, Certified Prosthodontists can help because they are trained to appropriately stage and manage complex treatment plans.

### 3. You have a demanding patient who wants perfect esthetics.

Examples include patients with a high smile line or needing a single tooth replacement in the esthetic zone. A Certified Prosthodontist is trained in selecting the best solutions for high-demand patients.

### 4. You have a question and want to discuss a case with a colleague to ease your mind.

A Certified Prosthodontist can be an excellent resource for you to ask questions because they are trained in many types of complicated treatments. For example, you may want to consult a Certified Prosthodontist for complex implant-supported restorations. They can work with you or complete the treatment for you to achieve the best in both function and esthetics.